



INTERNATIONAL JOURNAL OF PHARMACY AND ANALYTICAL RESEARCH

ISSN:2320-2831

IJPAP |Vol.7 | Issue 1 | Jan - Mar -2018

Journal Home page: www.ijpar.com

Research article

Open Access

Arma and pterygium

*Dr.Prakruthi G, **Dr.Hamsaveni V

*PG Scholar, Sri Kalabyraveswara Swamy Ayurvedic Medical College, Hospital and Research Centre, Bangalore, Karnataka, India.

**Professor., Dept. of PG Studies in Shalakya Tantra, Sri Kalabyraveswara Swamy Ayurvedic Medical College, Hospital and Research Centre, Bangalore, Karnataka, India.

*Corresponding Author: Dr.Prakruthi G

ABSTRACT

Disorders of the Conjunctiva are a common source of eye complaints, because the surface of the eye is exposed to various external influences. With age, the Conjunctiva can stretch and loosen from the underlying Sclera, leading to the formation of many disorders. Degenerative conditions are one such example. Degeneration refers to the process by which tissue deteriorates and loses its functional ability due to traumatic injury, aging and wear and tear. Pterygium, the commonest conjunctival degeneration is having the similarities with the disease *Arma* in our classics even with regards to both medical and surgical management. The prevalence rate of Pterygium vary widely from 2% to 29%, higher in tropics than temperate altitudes. Pterygium, usually affects aged persons, with more incidence in men. It may be unilateral or bilateral usually affecting the nasal than the temporal side. *Arma* is one among the *sandhigata rogas* as explained in our classics, is a *chedana sadhya vyadhi*. The methods adopted by our *acharyas* in performing the *shastra karma* are identical with the steps followed by the modern ophthalmologist even till date.

Keywords: Conjunctiva, Arma, Pterygium, Shastram karma.

INTRODUCTION

Conjunctiva is a translucent membrane which lines the posterior surface of the eyelids and anterior surface of the eye ball. The word meaning of conjoin is to join. The name is given to this mucous membrane owing to the fact that it joins eyeball to lids. [1] Pterygium, is derived from the Greek word *pterygos* means “wing”. Is a common ocular surface lesion originating in the Limbal conjunctiva within the palpebral fissure with

progressive involvement of the cornea. The lesion occurs more frequently at the nasal limbus than the temporal with a characteristic wing-like appearance [2]. The prevalence rate of Pterygium vary widely from 2% to 29%, higher in tropics than temperate altitudes.

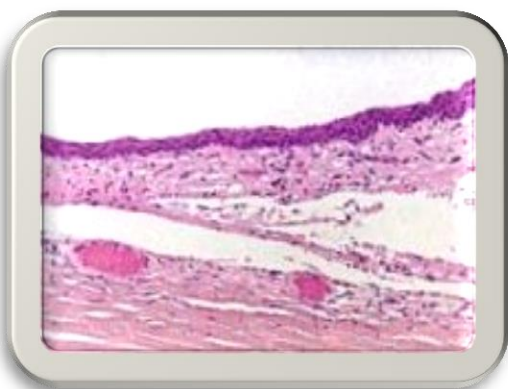Etiology

Not definitely known. Disease is more common in people living in hot climate. The most accepted view is, it is a response to prolonged effect of

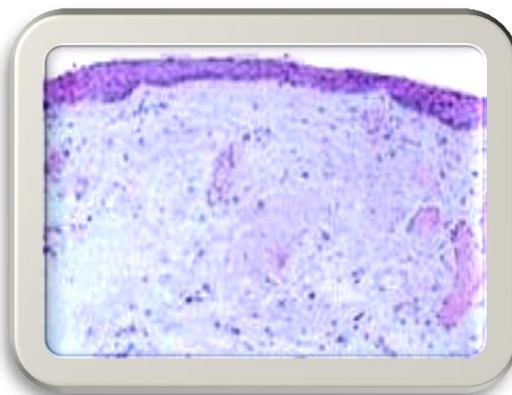
environmental factors such as sun (UV Light), dry heat, high wind and abundance of dust [3]. It forms as response to an acute inflammatory episodes of chemical burn, trauma, corneal ulcer, cicatrizing conjunctivitis [4].

Pathology

It is a degenerative and hyperplastic condition. Subconjunctival tissue undergoes elastotic degeneration then proliferates as vascularised granulation tissue under the epithelium, ultimately encroaches cornea. At last Corneal epithelium, Bowman's layer and superficial Stroma are destroyed [5].



Normal Conjunctiva.



Conjunctiva with Pterygium.

CLINICAL FEATURES [7, 8, 9]

Demography

Usually seen in old age, more common in males doing outdoor work than females.

Symptoms

Foreign body sensation, irritation and grittiness, cosmetic intolerance, otherwise asymptomatic in early stages, blurred vision, diplopia.

Signs

1. Raised, fibrovascular conjunctival growth within palpebral fissure, extending onto the corneal surface, white to pink in color depending on vascularity.
2. In early stages there will be minimal corneal involvement, later changes to a thick opaque vascular growth extending to the visual axis.

HISTOPATHOLOGY [6]

1. Histologically, pterygia are an accumulation of degenerated subepithelial tissue which is basophilic with a characteristic slate gray appearance on H&E staining.
2. Vermiform or elastotic degeneration refers to the wavy worm-like appearance of the degenerate fibers.
3. Destruction of Bowman's layer by fibrovascular ingrowth is typical.
4. The overlying epithelium is usually normal, but may be acanthotic, hyperkeratotic, or even dysplastic and often exhibits areas of goblet cell hyperplasia.

3. Vascular straightening in the direction of the advancing head of the Pterygium on the corneal surface.
4. It may affect the nasal and temporal limbus of both eyes (PRIMARY DOUBLE PTERYGIUM) or only a single location.
5. Pinguecula are often present in the ipsilateral or contralateral eye.
6. A pigmented epithelial iron line (Stocker's line) adjacent to a pterygium is evidence of chronicity.

Parts [10]

- HEAD: Apical part present on the cornea.
- NECK: Constricted part present in the limbal area.
- BODY: Scleral part, extending between limbus and the canthus.
- CAP: Semilunar whitish infiltrate present just in front of the head.

TYPES OF PTERYGIUM

Based on characteristic features [11]

- ❖ PROGRESSIVE TYPE : Thick, fleshy, vascular with few whitish infiltrates of cornea in front of the head of the pterygium – FUCH'S SPOTS OR ISLETS OF VOGT OR CAP OF PTERYGIUM.
- ❖ REGRESSIVE TYPE : Thin, atrophic, attenuated with very little vascularity. There is no cap, but deposition of iron – STOCKER'S LINE may be seen sometimes, just anterior to the head. Ultimately it becomes membranous but never disappears.

Based on extent of growth [12]

- ❖ Grade 1 – Midway between limbus and pupil border – less than or equal to 2mm onto cornea.
- ❖ Grade 2 – Extends up to pupil border – involve greater than 2– 4mm of cornea.
- ❖ Grade 3 – Crosses pupil more than or equal to 4mm of cornea and involve visual axis.

Based on laterality [13]

- ❖ Unilateral pterygium.
- ❖ Bilateral pterygium.

Based on location [14]

- ❖ Nasal pterygium (More common).
- ❖ Temporal pterygium.

Complications [15]

- ❖ Cystic degeneration.
- ❖ Infection.
- ❖ Fibrosarcoma.
- ❖ Epithelioma.
- ❖ Malignant melanoma.
- ❖ Corneal scarring.

Differential diagnosis [16]

- ❖ Pseudopterygium
- ❖ Pannus
- ❖ Congenital intraepithelial neoplasia.
- ❖ Terrien's marginal degeneration.
- ❖ Symblepharon.
- ❖ Steven Johnson syndrome.
- ❖ Limbal dermoid.
- ❖ Neurotrophic keratitis.

DIAGNOSIS [17]

1. The diagnosis is most often clear clinically.
2. Diagnosis is made by slit-lamp examination of the typical limbal growth at the characteristic location of 3 and 9 'o' clock position within the palpebral fissure.
3. Pterygoid lesions in other locations should elevate suspicion for alternate diagnosis.
4. Assessment of visual acuity and corneal topography can aid in determining the visual impact of Pterygia.

Treatment [18]

General treatment

- ❖ A number of potential therapeutic options exist for the management of Pterygia ranging from conservative management with lubrication to surgical excision with conjunctival autografts.
- ❖ Due to the potential for recurrence of a more aggressive lesion, as well as other surgical risks, the surgical removal of Pterygia should not be undertaken casually.

Medical therapy

- ❖ Inflamed Pterygia may cause irritation, foreign body sensation, and tearing which, in many cases, can be alleviated using vasoconstrictor drops, lubricating drops and ointments.

Medical follow up

- ❖ Initially, the corneal extension of the Pterygium should be measured and followed every 1 to 2 years to determine the rate of growth towards the visual axis.

SURGERY [19, 20, 21]

Indications for surgery

1. Cosmetic disfigurement.
2. Visual impairment due to significant regular or irregular astigmatism.
3. Continued progression threatening to encroach upon pupillary area (once it encroaches pupillary area, wait till it crosses on the other side).
4. Diplopia due to interference in ocular movements.

Pre-operative considerations

- ❖ A thorough history taking along with Comprehensive eye examination has to be done.

- ❖ Routine blood investigations has to be performed.
- ❖ Equipments and instruments required for the surgery should be arranged.

Pterygium set

1. Eye speculum.
2. Cataract knife.
3. Paufigue graft knife.
4. Paton corneal dissector.
5. Castroviejo needle holder.
6. Utility forceps.
7. Fixation forceps, 10mm wide jaws.
8. St. Martin forceps.
9. Scissors, curved.
10. Scissors, straight.

OPERATIVE

Surgical technique

1. After topical anaesthesia, eye is cleansed, draped and exposed using universal eye speculum.
2. Removal is effected by seizing the neck near the corneal margin with fixation forceps, raising it and shaving or dissecting it from the cornea, starting from the apex, taking care not to damage the underlying medial rectus muscle..
3. Main mass of pterygium is then freed from the sclera for about half the distance towards the canthus.
4. Two parallel incisions are then made with scissors to excise as much of the pterygium as possible. The head of the pterygium is then excised and a bare area of sclera remains at the edge of the cornea.
5. Haemostasis is achieved and the episcleral tissue exposed is cauterized thoroughly.
6. Conjunctival limbal autograft (CLAU) transplantation to cover the defect after excision.

Post-operative

- ❖ Bandaging should be done.
- ❖ Antibiotics should be used appropriately.
- ❖ Avoid sunlight exposure for the first 6 weeks after the procedure.
- ❖ Physically strenuous works should be avoided for about 3 weeks after the surgery.

Complications of surgery

- ❖ Recurrence.
- ❖ Corneal scarring.

- ❖ Infection.
- ❖ Epithelioma.
- ❖ Strabismus.
- ❖ Non healing epithelial defect.
- ❖ Scleral melt.
- ❖ Corneal perforation.

ADVANCES IN SURGERY

Conjunctival flap/graft

1. It is the latest and most effective technique. This is considered as the Gold Standard of care and carries an approximate rate of recurrence of 5-10% with minimal complications.
2. Use of fibrin glue to stick the auto graft in place reduces operating time as well as discomfort associated with sutures.
3. However, it is a lengthier procedure and technically slightly more complicated than the earlier methods.
4. Recently a major modification of a routine auto graft, known as P.E.R.F.E.C.T. for PTERYGIUM, has reduced the recurrence rate to 1/1000 and results in a cosmetic result where the appearance of the eye after this procedure is indistinguishable from that of a normal eye.

Prognosis:

- ❖ RECURRENCE OF THE PTERYGIUM is the main problem (30-40%).
- ❖ 97% of all recurrences occur in the first year after surgery.
- ❖ It cannot be removed without leaving a scar unless a lamellar corneal graft replaces it.

Recurrences can be reduced from following ways

1. Surgical excision with free conjunctival limbal auto graft taken from the same eye or the other is presently preferred.
2. Surgical excision with amniotic membrane graft and mitomycin-C (0.02%) application may be required in recurrent Pterygium or in large Pterygium.
3. Surgical excision with lamellar keratectomy and lamellar Keratoplasty may be required in deeply infiltrating recurrent recalcitrant Pterygia.
4. Old methods includes, McRaynold's operation (transplantation of Pterygium in lower fornix) and post operative use of beta irradiations.

Shukla mandala [22]

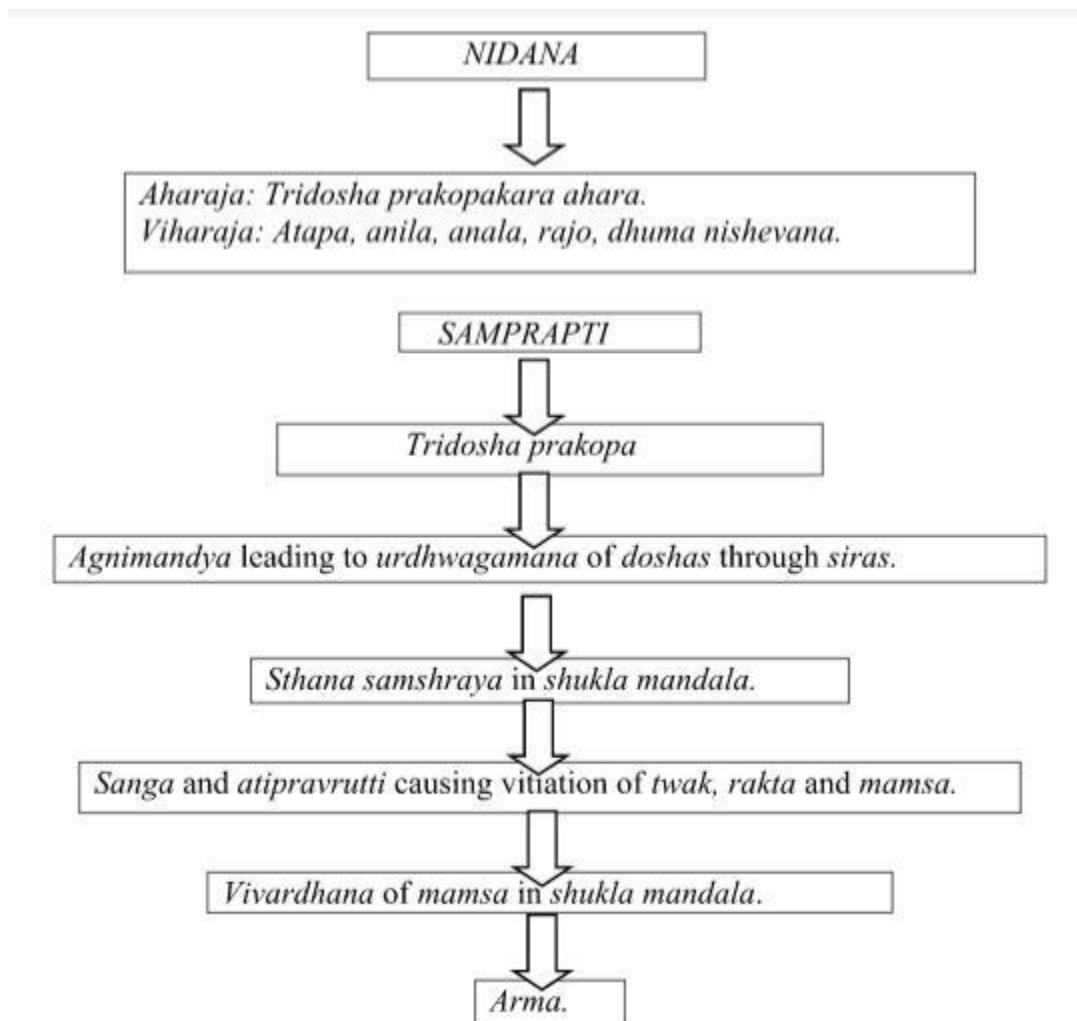
- The evolution and development of eye is dependent upon the action of *panchamahabhutas*.
- "Sitam jalat", the *bhoutika* composition of *sita* i.e., *shukla mandala* is attributed to *jala mahabhuta*, indicating the predominance of *kapha dosha*.
- *Shukla mandala* is the visible white portion of the eye.
- The *sthira*, *snigdha* and *guru gunas* of *kapha* provides shape and stability to eye ball through *shukla mandala*.
- *Sandhi* and *mandalas* related to *shukla mandala*:

1. In the periphery-*vartmamandala-vartmashuklagata sandhi*.
2. In the centre – *krishnamandala – shuklakrishnagata sandhi*.
3. Medially – *kaninika sandhi*.
4. Laterally – *Apanga sandhi*.

Arma

- ❖ Derived from *ru dhatu* and *manin pratyaya* – *arman*.
- ❖ *Shyati gacchati iti arma* – that which grows gradually.
- ❖ *Arma* is a *mamsavruddhi* over the *shukla mandala* which grows gradually invading the deeper structures.

SAMPRAPTI



Samprapti ghataka

Dosha: Depending on the type of *arma*.

Dushya: Depending on the type of *arma*.
Mainly *twak*, *rakta*, *mamsa*.
Agni: *Jataragni*, *sthanika dhatwagni*.

Srotas: Rasa, rakta, mamsavaha srotas.

Srotodushti prakara: Sanga, atipravrutti, siragranthi.

Udbhava sthana: Amashaya.

Vyaktha sthana: Shukla mandala.

Adhistana: Netra.

Roga marga: Madhyama.

Sadhyasadyata: Shastra sadhya.

Pratyatma lakshana: Vivardhana of mamsa.

PURVA ROOPA: Samrambha, ashru, raga, toda.

ROOPA: It is based on type of arma.

TYPE OF ARMA	LAKSHANAS	DOSHA	DHATU	NATURE OF GROWTH	COLOUR	NATURE OF MASS	SADHYA-ASADHYATA
PRASTARI	A thin, soft, fleshy reddish or bluish colour growth over <i>shukla mandala</i> having broad base and spreading continuously. It is so called because of its <i>prasarana sheelata</i> .	<i>Tridosha</i>	<i>Rakta, mamsa</i>	Fast growing.	Reddish or bluish.	Thin growth.	<i>Chedana sadhya.</i>
LOHITA	<i>Mamsala</i> growth over <i>shuklabhaga</i> which resembles <i>padma</i> i.e lotus petals. It is also called as <i>kshatajarma</i> .	<i>Rakta</i>	<i>rakta</i>	Growing	<i>Rakta</i>	Soft and bulky.	<i>Chedana sadhya.</i>
ADHIMAMSA	<i>Mrudu, vistirna</i> (extended), <i>bahala</i> (thick), <i>yakrut samana</i> , <i>shyavavarna</i> <i>adhika mamsa</i> over the <i>shukla</i> .	<i>tridosha</i>	<i>mamsa</i>	Spreading	Greyish white.	Soft and bulky.	<i>Sannipataja chedana sadhya.</i>
SHUKLA	<i>Mrudu</i> slowly growing whitish growth in <i>shukla bhaga</i> .	<i>Kapha</i>	<i>mamsa</i>	Atrophic mass.	White	Soft	<i>Chedana sadhya.</i>

SNAYU	<i>Khara, pandura tridosha mamsa</i>	Atrophied.	brown	Rough	<i>Chedana</i>
	<i>varnaja, slowly progressing muscular growth.</i>			and dense	<i>sadhya</i>

Chikitsa

- ❖ The classification of *Arma* should be done as *lekhana sadhya* and *chedana sadhya*.
- ❖ Indications of *lekhana sadhya arma dadhinibha* (looking like curds), *neelam*(bluish), *raktam*(reddish), *dusaram*(greyish), *tanu*(thin) – Su.Ut.15/17.
- ❖ Treatment of *krishnagata rogas* and *pittaja abhishyanda* has to be adopted – Y.R-Netra.
- ❖ *Panchakarma*:
Kaya vireka and *shirovireka* – A.S.Ut.14/9.
Nasya karma with *krishnadi yoga* – Vangasena-Netra.

Other medications

- ❖ *Marichadi lepa* - *Yoga ratnakara, netrarogadhikara*.
- ❖ *Karparadi anjana* – *Vyadhi nigraha, Vishramayati*.
- ❖ *Krishnalohadi putapaka and anjana* - *Yoga ratnakara, netrarogadhikara*.
- ❖ *Pippalyadi gutikanjana* - *Yoga ratnakara, netrarogadhikara*.
- ❖ *Pushpaakshadi rasakriya* - *Yoga ratnakara, netrarogadhikara*.
- ❖ *Nayana sukha varti* – *Bhaisajya ratnavali* – 64/199.

Oral medications:

- ❖ *Shadanga guggulu* - *Chakradatta*, 59/46.
- ❖ *Vasakadi kwatha* - *Chakradatta*, 59/47.
- ❖ *Brhat vasadi kwatha* – *Chakradatta*, 59/48-50.
- ❖ *Satavaryadi churna* - *Yoga ratnakara, netrarogadhikara*.
- ❖ *Mahatriphaladi ghrta* – *Yoga ratnakara, netra rogadhikara*.
- ❖ *Lohadi guggulu* – *Yoga ratnakara, netrarogadhikara*.

Shastra karmasadhya lakshana (SU.UT.15/18)

- ❖ Very thick – *charmabha*.
- ❖ Highly elevated – *bahala*.
- ❖ Fleshy growth covered densely with fibrous tissues – *snayu-mamsa avrita*.

- ❖ Encroaching *krishna mandala* – *krishna mandalaga*.
- ❖ Visible blood vessels.

Shastra karma asadhya lakshana

- ❖ If *Arma* is already encroached the *drushti mandala*, it is a sign of incurability and surgery should be avoided in such cases as *acharya Vagbhata* clearly explains “*drushti praptam tu varjayet*”.

ARMA CHEDANA VIDHI [23, 24]

Poorva karma

- ❖ Patient should be given *Snehayukta ahara* and *ghrita*.
- ❖ Should offer prayer.
- ❖ Patient has to lie down in head low position on even bed.
- ❖ Fomentation has to be given for *netra* with a cotton dipped in *sukhoshna jala*.
- ❖ *Nayana samroshana* using *saindhava* and *Bijapuraka* over the *arma*.
- ❖ *Sushruta* says “*Parighatitam*” which means *shithilikarana* of *arma*.

Pradhana karma

- ❖ Patient is asked to look laterally.
- ❖ *Shithila arma* has to be lifted using *Badisha yantra*.
- ❖ After lifting, it has to be held in *muchundi* or *suchi yantra* and elevated.
- ❖ The lids should be held apart tightly as there is a risk of being hurt by the *yantras*.
- ❖ The *Arma* thus elevated should be dissected from all the sides with *mandalagra shastra*.
- ❖ It should be removed after freed from all the sides sparing the *canthus*.
- ❖ The one-fourth *Arma* should be retained at its attachment.

Paschat karma

- ❖ *Pratisarana* with *yavanala, trikatu* and *saindhava*.

- ❖ *Pariseka*: After cleaning the part with sterilised gauze and *madhu*, it has to be washed with *shitambhu* and *sukhoshna sarpi*.
- ❖ *Vrana bandhana* has to be done after applying *ghrita* and *madhu*.
- ❖ *Sheeta pradeha*: For head and soles, *shata dhouta ghrita* has to be applied.
- ❖ The luke warm mixture of *madhu* and *ghrita* should be applied to the head and eyes keeping the bandage intact on the second day morning, afternoon and night.
- ❖ On third day, bandage should be removed and *swedana* should be given with *karanjabeeja siddha ksheera*.
- ❖ For five days, *ghrita* should be given orally with *ushna jala* as *anupana* followed by *pathya bhojana*.
- ❖ *Aschyotana* should be done with the decoction of *Lodhra, Yashti, Palasa, Patola, Haridra, Daru Haridra* mixed with honey and bandaged for the next seven days.
- ❖ Later bandage can be opened completely. But care should be taken to avoid direct sunlight and viewing the sky or other luminous objects.

Management of complications

- ❖ If associated with *Shopha*, then *dhumapana* and *shiro virechana*.
- ❖ *Anupashante - sira visravana*.
- ❖ *Sasrave - nasya*.
- ❖ If there is any damage to *krishna mandala* during surgery, it should be treated like *Savrana shukla*.
- ❖ *Shesha arma* has to be treated with *Lekhananjanas*.

Note

Shesha arma chikitsa has to be done by Nagara manahshiladi varti prayoga.

Samyak chinna lakshana

The features of proper excision of *Arma* will ensure anatomical and physiological normalcy. According to *Vagbhata: Varna vishuddhi* and *swastata* are the features of proper surgery.

Hinacheda and aticheda lakshana

If it is a *hina cheda*, *Punarvrudhi*, *raga*, *ashrupata*, *prakashadarshana akshamatwa*. If it is a *ati cheda*, *akshipaka*, *stambha*, *sphurana*, *asrasruti*, *timira*, *samrambha*, *viddhavartma*.

Treatment

Depends on the *doshic* predominance.

DISCUSSION

- ❖ *Arma* is a disease having exact similar entities to Pterygium explained in modern science with absolute medical and surgical treatment.
- ❖ As *dosha* concerned with degeneration, *vata* comes in to play where even the modern ophthalmologist have accepted that the degenerations concerned to conjunctiva becomes more common with age.
- ❖ proper understanding of the characteristic features of *Arma* are diagnostically valuable, because it reflects the *dosha* predominance and the pathological change.
- ❖ Among the five types of *Arma*, signs and symptoms of *Prastari, Lohitarma* and *Adhimamsaja Arma* indicates the progressive phase of the disease, *Shuklarma* and *Snayu Arma* indicates the phase where growth is almost retarded representing the regressive phase of the disease.
- ❖ In the view of allied sciences, surgical removal of Pterygium is typically only recommended if the ability to see is affected where even our *acharyas* have clearly explained the *Arma* which should be taken for surgical excision (*asitapraptam*) and which should not be taken for excision (*drushtipraptam cha varjayet*).
- ❖ Instruments and techniques used by our *acharyas* in those days in *Arma chedana vidhi* is still now being practiced by modern surgeons.
- ❖ Even though the advanced technologies are introduced in modern field of ophthalmology with regards to surgical removal, recurrence is still 5-10 percent.
- ❖ The postoperative care in case of Pterygium is very much similar to *pashchat karma* of *Arma*.
- ❖ The drugs used to treat *shesha arma* like *triphala*, *haridra*, *guduchi*, *nimbi*, *guggulu*, *pippali* has anti-angiogenic properties which helps to stop the further growing of *arma* thereby it checks recurrence.

CONCLUSION

In all ayurvedic classics, arma is described under shuklagata netra roga, is a chedana sadhya vyadhi. Our acharyas have described aushadha chikitsa i.e., shukravat chikitsa in the form of lekhaana anjana, seka, lepa, pratisarana for arma in alpa, tanu, dadhinibha, rakta, neela or dhusara varna. Clinical features and management of arma simulates that of Pterygium in modern science.

“Prevention is better than cure”, conjunctiva, the most superficial layer of the eyeball and hence utmost care and all precautionary measures should be taken to avoid its degeneration. Vata being the main causative factor for degeneration regular padabhyanga, intake of ghrita, shiroabhyanga has to be advocated in every individual who are under risk factors. In our classics, in view of arma nidana, chatra dharana, shirastrana measures to be observed regularly.

REFERENCES

- [1]. A K Khurana & Aruj K Khurana. Comprehensive Ophthalmology. New Delhi. Jaypee Brothers Medical Publishers (P) Ltd. 6, 623, 59.
- [2]. American Academy of Ophthalmology – Eye Wiki.
- [3]. A K Khurana & Aruj K Khurana. Comprehensive Ophthalmology. New Delhi. Jaypee Brothers Medical Publishers (P) Ltd. 6, 623, 87,88.
- [4]. Jack J Kanski. Clinical ophthalmology A Systematic approach. London. Butterworth Heinemann. 5, 2003, 242.
- [5]. A K Khurana & Aruj K Khurana. Comprehensive Ophthalmology. New Delhi. Jaypee Brothers Medical Publishers (P) Ltd. 6, 623, 87, 88.
- [6]. American Academy of Ophthalmology – Eye Wiki.
- [7]. A K Khurana & Aruj K Khurana. Comprehensive Ophthalmology. New Delhi. Jaypee Brothers Medical Publishers (P) Ltd. 6, 623, 88.
- [8]. American Academy of Ophthalmology – Eye Wiki.
- [9]. Ramanjit Sihota & Radhika Tandon. Parsons’ Diseases of the Eye. New Delhi. Elsevier- A division of Reed Elsevier India Pvt. Ltd. 21, 2011. 184.
- [10]. A K Khurana & Aruj K Khurana. Comprehensive Ophthalmology. New Delhi. Jaypee Brothers Medical Publishers (P) Ltd. 6, 623, 88.
- [11]. Jack J Kanski. Clinical ophthalmology A Systematic approach. London. Butterworth Heinemann. 5, 2003, 242.
- [12]. Ramanjit Sihota & Radhika Tandon. Parsons’ Diseases of the Eye. New Delhi. Elsevier- A division of Reed Elsevier India Pvt. Ltd. 21, 2011. 184.
- [13]. American Academy of Ophthalmology – Eye Wiki.
- [14]. A K Khurana & Aruj K Khurana. Comprehensive Ophthalmology. New Delhi. Jaypee Brothers Medical Publishers (P) Ltd. 6, 623, 88.
- [15]. American Academy of Ophthalmology – Eye Wiki.
- [16]. Ramanjit Sihota & Radhika Tandon. Parsons’ Diseases of the Eye. New Delhi. Elsevier- A division of Reed Elsevier India Pvt. Ltd. 21, 2011. 184.
- [17]. *Sushruta Samhita, with Sri Dalhanacharya teeka, edited by Narayan Ram Acharya “Kavyathirtha”, Chaukhambha orientalia, Varanasi, reprint edition-2009, Uttaratanttra, 18(6), 824,596.*
- [18]. *Sushruta Samhita, with Sri Dalhanacharya teeka, edited by Narayan Ram Acharya “Kavyathirtha”, Chaukhambha orientalia, Varanasi, reprint edition-2009, Uttaratanttra 18(6), 824, 622-623.*
- [19]. *Ashtanga sangraha of vriddha vagbhata with the Shashilekha Sanskrit commentary by Indu, edited by Dr.Shivprasad Sharma, sutra sthana,chapter-33(2), 964,697-698.*